Comparative Toxicity of Selenium from Seleno-DL-methionine, Sodium Selenate, and *Astragalus bisulcatus* in Pigs

K. E. PANTER,* W. J. HARTLEY,† L. F. JAMES,* H. F. MAYLAND,‡ B. L. STEGELMEIER,* AND P. O. KECHELE*

*USDA–ARS Poisonous Plant Research Laboratory, Logan, Utah 84341; †Taronga Zoo, P.O. Box 20, Mosman, NSW 2088, Sydney, Australia; and ‡USDA–ARS Northwest Irrigation and Soils Research Laboratory, Kimberly, Idaho 83341

Received September 5, 1995; accepted April 26, 1996

Comparative Toxicity of Selenium from Seleno-DL-methionine, Sodium Selenate, and *Astragalus bisulcatus* in Pigs. PANTER, K. E., HARTLEY, W. J., JAMES, L. F., MAYLAND, H. F., STEGELMEIER, B. L., AND KECHELE, P. O. (1996). *Fundam. Appl. Toxicol.* 32, 217–223.

Selenium is an essential micronutrient, although ingestion in excess in pigs can cause disease conditions including neurological dysfunction and chronic skin and hoof lesions. Controlled feeding trials in growing swine, using the same Se content in feed sources, resulted in higher concentrations ($p \leq 0.05$) of Se in blood and organs of pigs fed seleno-DL-methionine compared with those receiving *Astragalus bisulcatus* or sodium selenate. Clinical signs of Se toxicity including neurological signs of paralysis were more severe and occurred sooner in the *A. bisulcatus* group than in the sodium selenate or seleno-DL-methionine groups. All five pigs fed *A. bisulcatus* developed neurological signs of paralysis, and in four the signs occurred within 5 days of the start of treatment. Four of five pigs fed sodium selenate also developed paralysis, but this occurred 4 to 21 days after treatment began. The fifth pig in the group developed signs of chronic selenosis. Two of five pigs fed seleno-DL-methionine developed paralysis on 9 and 24 days, respectively, and the remaining three developed chronic selenosis. Selenium fed to pigs in three forms [plant (*A. bisulcatus*), sodium selenate, or seleno-DL-methionine] resulted in neurological dysfunction and lesions of symmetrical poliomyelomalacia. These were most severe in the *A. bisulcatus* group, which also had polioencephalomalacia. Although seleno-DL-methionine caused the greater increase in tissue and blood Se concentrations, this did not correlate with severity of pathological changes, since animals fed *A. bisulcatus* developed more severe and disseminated lesions.

Field observation and experimental trials in the United States have shown a great variety of syndromes and pathology resulting from ingestion of certain species of *Astragalus* by livestock. The syndromes include disease conditions induced by the nitro-containing *Astragalus* (*A. miser*), the swainsonine-containing *Astragalus* (*A. lentiginosus*, locoweeds), and the selenium-containing *Astragalus* (*A. bisulcatus*). These syndromes have been reviewed by James *et al.* (1981).

Two Se-accumulating plants (*A. bisulcatus* and *A. praelongus*) and inorganic Se compounds have been shown to produce neurological signs and microscopic lesions of focal symmetrical polioencephalomalacia and poliomyelomalacia when fed to young pigs (Hartley *et al.*, 1984). Both plant species also contain small amounts of swainsonine, an α-mannosidase inhibitor that causes the lesions and clinical syndrome known as locoism. This toxin might contribute to the development of lesions when animals are poisoned eating these plants. In previous studies of Se intoxication, organic Se was fed to growing pigs in the form of selenocystine. The animals failed to thrive and had varying degrees of hepatic fibrosis, but neither neurological signs nor histological lesions were seen in the central nervous system (Hartley *et al.*, 1984). The biochemical parameters of some of these pigs have been reported (Baker *et al.*, 1989). This report details additional trials including dosing with seleno-DL-methionine (organic form of Se) and a comparison of the resulting tissue Se and histological lesions with those seen in animals treated with sodium selenate (inorganic form of Se) or *A. bisulcatus* (nonprotein, water-soluble plant forms of Se) at the same Se dose.

MATERIALS AND METHODS

Twenty, 8- to 10-week-old pigs were allotted to four treatment groups of five each. All groups were penned separately and fed a commercial pig ration containing 0.4 μg Se/g dry wt. The treatment groups were fed the same ration to which either seleno-DL-methionine (Sigma Chemical Co., Lot No. s-3875), sodium selenate, (ICN Pharmaceuticals, Lot No. 33370-A), or *A. bisulcatus* (300 μg/g Se) was added to give a final diet concentration of 25 μg Se/g. The feed intake in these three groups was adjusted so that each animal received approximately the same amount of feed and a calculated average intake of 25 mg Se/day for up to 6 weeks. The pigs were fed treatment diets for 6 weeks or until they showed paralysis (either general or lumbar), at which time they were humanely killed and necropsied.

All pigs were bled weekly and whole blood was taken in heparinized tubes and frozen for Se analysis. Liver, kidney, spleen, heart, lung, brain, and spinal cord sections (specifically the cervical and lumbar enlargements) were collected at necropsy, freeze-dried, and analyzed for selenium by a fluorometric method (Olson, 1969).

The precision and accuracy of the Olson fluorometric method were monitored by randomly placing standard plant and animal tissue samples in the

USDA - AGRICULTURAL RESEARCH SERVICE
Poisonous Plant Research Laboratory
1150 East 1400 North
Logan, UT 84341
Ph. (801) 752-2941

0272-0590/96

sequence of unknown feed and porcine tissues subjected for analysis. The standards, our laboratory results, number of samples, and the certified or accepted value are shown below:

Wheat flour NIST No. 1567, 1.02 ± 0.08 mg Se/kg, n = 21, certified 1.1 ± 0.2

Bovine liver NIST No. 1577a, 0.72 ± 0.07 mg Se/kg, n = 22, certified 0.71 ± 0.07

Citrus leaves NIST No. 1572, 0.036 ± 0.002 mg Se/kg, n = 7, 0.025 not certified

Alfalfa internal sample analyzed as 0.437 ± 0.04 mg Se/kg, n = 9

Bovine liver, IMVS Australian standard, 1.1 ± 0.07 mg Se/kg, n = 23, mean of international laboratories: 1.068 ± 0.06 mg Se/kg

These results verify a highly acceptable precision and accuracy of Se analyses of plant and animal tissue in this laboratory.

Similar tissues, including the entire central nervous system, were also collected, fixed in 10% buffered formalin, and prepared for histopathological examination.

The values for whole blood and tissue Se were transformed to their natural logarithm to stabilize variances and provide a more normal distribution and statistically analyzed by analysis of variance procedures; means were compared by Fisher's least significant difference test (SAS, 1987). Arithmetic means are reported in this text.

RESULTS

Tables 1 to 3 summarize the effects of seleno-DL-methionine, sodium selenate, and *A. bisulcatus* on clinical signs, weight change, severity of pathological lesions, and Se concentrations in blood and tissues at the time the pigs were killed.

Clinical. All but one of the five pigs in the *A. bisulcatus* group became paralyzed and were killed within 5 days of feeding. The fifth pig survived 3 weeks longer before neurological signs appeared. All but one of the sodium selenate group developed neurological signs 4 to 21 days after feeding commenced, and the other developed signs of chronic selenosis by the termination of the trial. Chronic selenosis occurred in three pigs in the seleno-DL-methionine group and in one in the sodium selenate group, characterized as poor weight gain, symmetrical hair loss, dry scaling skin, and cracked, overgrown hooves. In the seleno-DL-methionine group, two pigs developed neurological signs, one at 9 and one at 24 days. They also had poor weight gains.

TABLE 1
Effects of Different Sources of Selenium on Various Physiological Parameters in Groups of Pigs (N = 5)

Treatment	Days on trial (mean ± SD)	Clinical signs	Weight change (%)
Seleno-DL-methionine (25 μg Se/g)	31 ± 14	3/5 = KS[a] 2/5 = KN	+18
Astragalus bisculcatus (25 μg Se/g)	7.6 ± 9.2	5/5 = KN	−5
Sodium selenate (25 μg Se/g)	16 ± 16	1/5 = KS 4/5 = KN	+11
Controls (0.4 μg Se/g)	33 ± 9	5/5 = K	+33

[a] KN, killed with CNS signs; KS, killed with skin lesions of chronic selenosis; K, killed normal.

Pathology. All pigs showing neurological signs (Table 2) had histological lesions in the central nervous system characteristic of those seen in Se-associated focal symmetrical poliomyelomalacia (Figs. 1 and 2). This malacia or liquefactive necrosis is characterized by spongiform changes with neuropil vacuolation, neuronal pyknosis and necrosis, accumulation of debris-laden gitter cells, mild gliosis, satellitosis, and multifocal hemorrhage. Some sections are congested with perivascular edema and eosinophilic inflammatory cell infiltrates. Minimal changes are present in the adjacent white matter. This poliomyelomalacia was most severe in the *A. bisulcatus* group, which also had polioencephalomalacia (Fig. 3). Lesions in animals of the sodium selenate and seleno-DL-methionine groups were similar but less severe and lacked the extensive brain lesions seen in the *A. bisulcatus* group. The lesions in all groups were most severe in the sacral and lumbar intumescences. Histological lesions were not observed in other tissues except for diffuse hepatocellular vacuolation observed in pigs fed *A. bisulcatus* for 2 weeks or longer. This vacuolation may be due to the locotoxin swainsonine (Molyneux *et al.*, 1984); however, the extensive fine neuronal or visceral vacuolation that is characteristic of locoism was not seen. Chronic lesions of skin, hooves, and hair were not described histologically.

Selenium analyses. Whole blood Se values were significantly higher ($p \leq 0.05$) in the sodium selenate, *A. bisulcatus,* and seleno-DL-methionine groups compared with controls at Week 1 (Fig. 4). Selenium values were also higher than controls in Weeks 2–5; however, only one animal was sampled from the *A. bisulcatus* group at Week 3 and one animal from the sodium selenate group in Weeks 4 and 5. The general trend was for the seleno-DL-methionine group to be higher than the other selenium groups, although this was significant only at Week 1 and at necropsy ($p \leq 0.05$). Selenium concentrations in whole blood taken at necropsy were significantly ($p \leq 0.05$) higher for seleno-DL-methionine pigs than for sodium selenate, *A. bisulcatus,* and control pigs. Whole blood Se values were not different between *A. bisulcatus* and sodium selenate groups ($p \geq 0.05$), but both were higher than controls ($p \leq 0.05$). Liver, kidney, spleen, heart, lung, brain, and spinal cord Se values were markedly higher ($p \leq 0.05$) in the seleno-DL-methionine group compared with the sodium selenate and *A. bisulcatus* groups; all selenium groups had higher tissue Se than controls ($p \leq 0.05$, Table 3). One needs to remember that tissue and terminal blood Se values were compared at necropsy, which occurred after different lengths of time on the seleniferous diets.

TABLE 2
Severity of Lesions in Pigs Fed Different Sources of Selenium

Treatment and pig No.	Brain lesions						Cord lesions						CNS signs[a]	Chronic selenosis[b]
	Midstem			Poststem			CE			LE				
	A	B	C	A	B	C	A	B	C	A	B	C		
Control														
2	0[c]	0	0	0	0	0	0	0	0	0	0	0	—	—
4	0	0	0	0	0	0	0	0	0	0	0	0	—	—
14	0	0	0	0	0	0	0	0	0	0	0	0	—	—
23	0	0	0	0	0	0	0	0	0	0	0	0	—	—
24	0	0	0	0	0	0	0	0	0	0	0	0	—	—
Se-DL-methionine														
3	0	0	0	0	0	0	2	2	0	2	3	0	++	—
6	0	0	0	0	0	0	0	0	0	0	0	0	—	++
8	0	0	0	1	0	0	1	4	4	0	4	4	++	—
20	0	0	0	0	0	0	0	0	0	0	0	0	—	++
27	0	0	0	0	0	0	0	0	0	0	0	0	—	++
Astragalus bisulcatus														
5	1	0	0	2	0	0	3	2	1	3	3	1	+++	—
10	0	0	0	1	0	0	1	0	0	2	0	0	++	—
13	2	0	0	2	0	0	2	3	2	2	3	2	+++	—
16	3	3	1	4	3	2	2	2	3	2	4	3	+++	—
28	4	2	2	3	0	0	3	1	2	2	1	2	+++	—
Na selenate														
9	2	0	0	1	0	0	3	2	0	2	3	0	+++	—
11	1	0	0	1	0	0	2	3	0	3	3	0	+++	—
18	0	0	0	1	0	0	2	1	0	2	2	0	++	—
22	0	0	0	0	0	0	0	0	0	0	0	0	—	++
26	0	0	0	0	0	0	1	3	1	3	3	1	+++	—

Note. A, spongy vacuolation; B, neuronal degeneration; C, gliosis and phagocytes; CE, cervical enlargement; LE, lumbar enlargement.
[a] Type of CNS signs: —, no effect; +, posterior ataxia; ++, posterior paralysis; +++, complete paralysis.
[b] Chronic selenosis: —, none observed; ++, hair loss, skin and hoof lesions.
[c] 0–4 = arbitrary assessment of severity of changes: 0 = no effect, 4 = severe effect.

TABLE 3
Average[a] Tissue Selenium Concentrations (μg/g fresh tissue) at Necropsy in Pigs Fed Different Sources of Selenium

Treatment	Whole blood	Liver	Kidney	Spleen	Heart	Lung	Brain	Spinal cord
Seleno-DL-methionine (25 μg Se/g)	$^{A}5.6 \pm 1.6$	$^{A}64.6 \pm 24.2$	$^{A}118.3 \pm 39.2$	$^{A}75.9 \pm 26.8$	$^{A}57.6 \pm 33.9$	$^{A}46.8 \pm 20.8$	$^{A}31.0 \pm 17.6$	$^{A}13.5 \pm 6.7$
Astragalus bisulcatus (25 μg Se/g)	$^{B}2.0 \pm 1.2$	$^{B}12.4 \pm 3.4$	$^{B}16.6 \pm 2.1$	$^{B}4.9 \pm 1.2$	$^{B}3.9 \pm 0.5$	$^{B}5.8 \pm 0.9$	$^{B}3.4 \pm 0.8$	$^{B}1.4 \pm 0.2$
Na selenate (25 μg Se/g)	$^{B}2.4 \pm 0.3$	$^{B}12.9 \pm 2.3$	$^{B}20.1 \pm 2.3$	$^{B}7.1 \pm 2.7$	$^{B}7.3 \pm 1.6$	$^{B}9.1 \pm 0.3$	$^{B}3.0 \pm 0.2$	$^{B}2.1 \pm 0.2$
Controls (0.4 μg Se/g)	$^{C}0.3 \pm .04$	$^{C}2.3 \pm 0.2$	$^{C}7.2 \pm 0.3$	$^{C}2.1 \pm 0.2$	$^{C}1.8 \pm 0.1$	$^{C}1.6 \pm 0.2$	$^{C}1.2 \pm 0.1$	$^{C}0.4 \pm .06$

[a] Means with different letters in a column are significantly different ($p \leq 0.05$). The means and standard deviations reported are of the original data. For statistical analysis the data were transformed to log y to stabilize variances and provide a more normal distribution, then analyzed by ANOVA and means separated by Fisher's LSD (SAS, 1987).

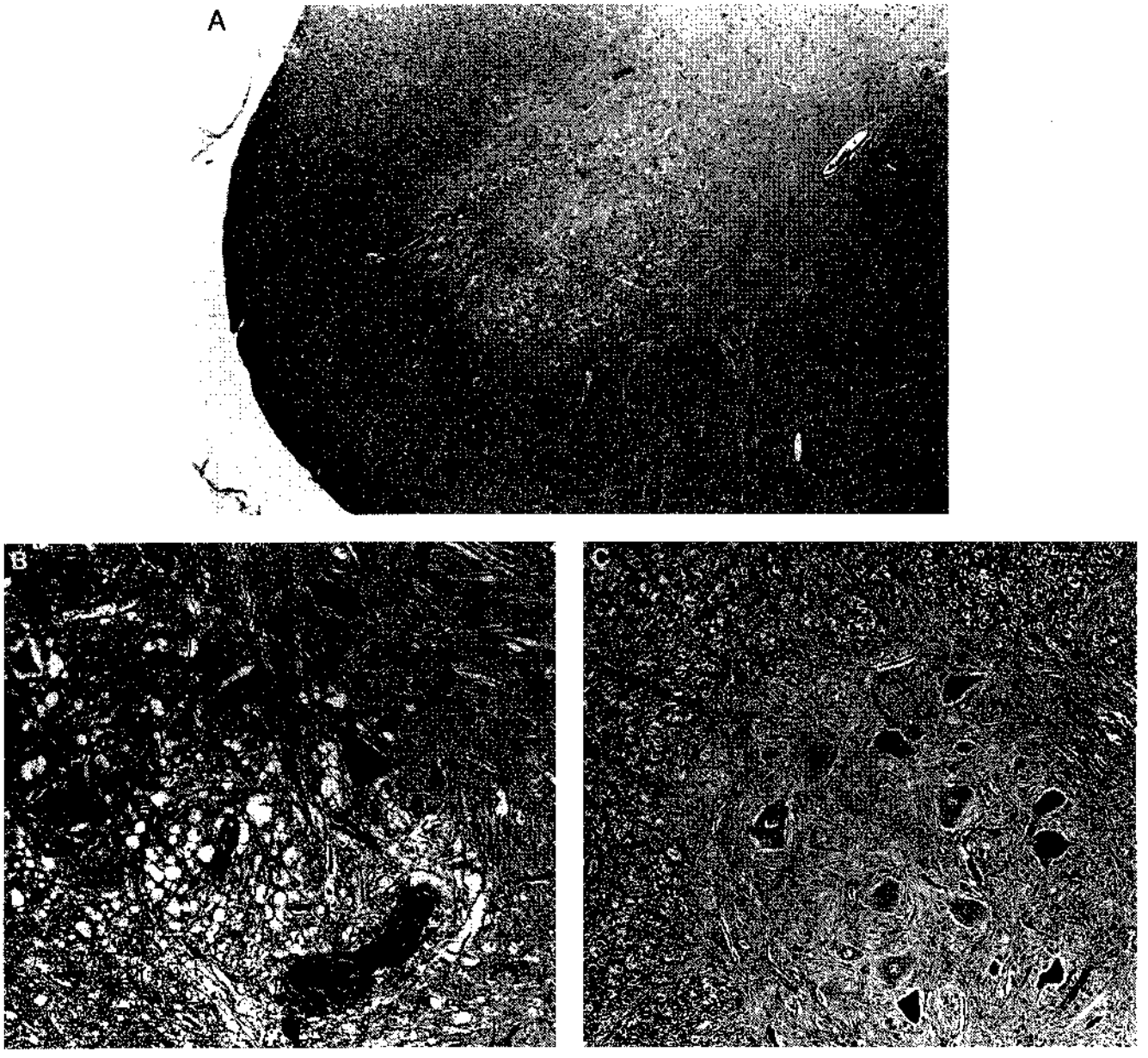

FIG. 1. Poliomyelomalacia in the ventral gray matter of the lumbar enlargement of the spinal cord from a pig fed a growing ration containing 25 μg Se/g as *Astragalus bisulcatus* for 24 days. H&E stain. (A) ×10; (B) ×100; (C) section of ventral gray matter of the lumbar enlargement of the spinal cord from a control pig, ×100.

DISCUSSION

Herigstad *et al.* (1973) reported extensive experimental trials feeding 4-week-old piglets with different levels of Se as sodium selenate and seleno-DL-methionine, both on a torula yeast basic diet and milk diet. Examination of their analytical data, however, shows higher values of Se in liver and kidney of the seleno-DL-methionine-dosed animals compared with sodium selenite groups; poliomyelomalacia was reported in only two pigs.

Our findings further confirm the association between Se in several forms and focal symmetrical poliomyelomalacia. These lesions were most severe in the *A. bisulcatus* group in which encephalomalacia was also described (Table 2, Fig. 3). We also confirm the observations of Herigstad *et al.* (1973), as in our trials there was a twofold increase in blood Se values (Fig. 4) and a marked increase in certain tissue Se concentrations in the seleno-DL-methionine group compared with the sodium selenate group (Table 3). The reason for this increased absorption and storage of Se in the seleno-

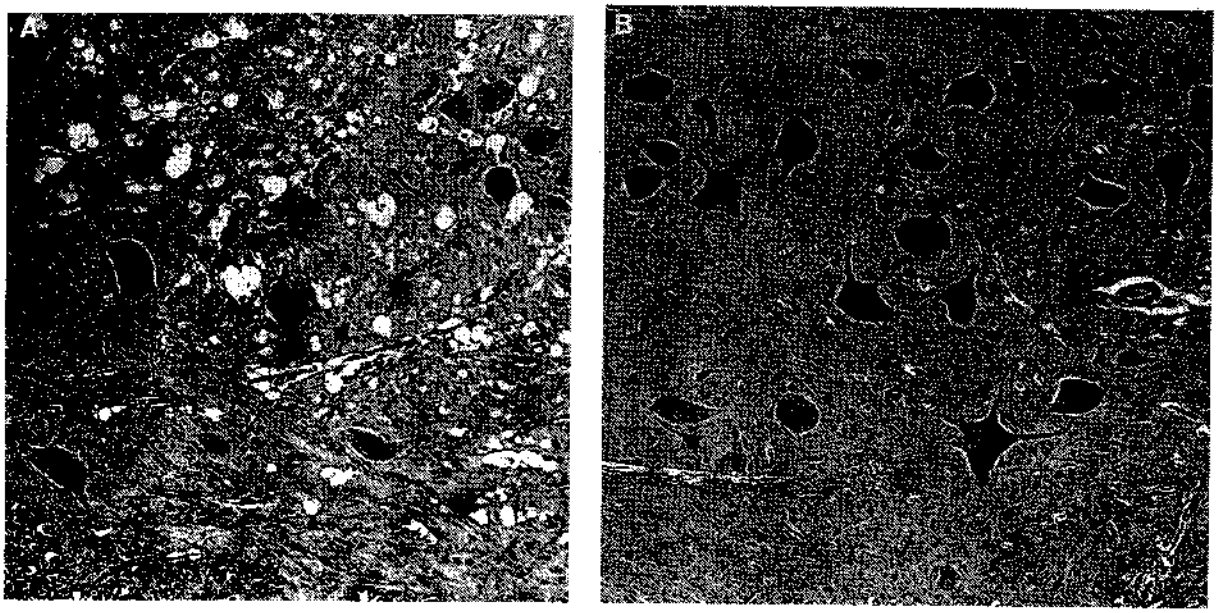

FIG. 2. (A) Poliomyelomalacia in the ventral gray matter of the cervical enlargement from a pig fed a growing ration containing 25 μg Se/g as *Astragalus bisulcatus*. H&E stain; ×100. (B) Section of ventral gray matter of the cervical enlargement of the spinal cord from a control pig, H&E stain; ×100.

DL-methionine group is apparently due to the direct incorporation of this organic form of Se into protein (Combs and Combs, 1986). This is supported by the relative bioavailability of selenomethionine, reported to be three to four times that of sodium selenite (Combs and Combs, 1986). Experiments *in vitro* and *in vivo* have demonstrated that selenomethionine is readily absorbed through the gut. Selenomethionine was absorbed two times faster than selenocystine and four times faster than selenite (Reasbeck *et al.*, 1981). As seleno-DL-methionine is transported at a rate about half that of L-selenomethionine, it is likely that L-selenomethionine is taken up by the same mechanism as L-methionine



FIG. 3. Polioencephalomalacia in the thalmus (A) and superior colliculus of the corpora quadragemina (B) in a pig fed a growing ration containing 25 μg Se/g as *Astragalus bisulcatus* for 24 days. H&E stain; ×100.

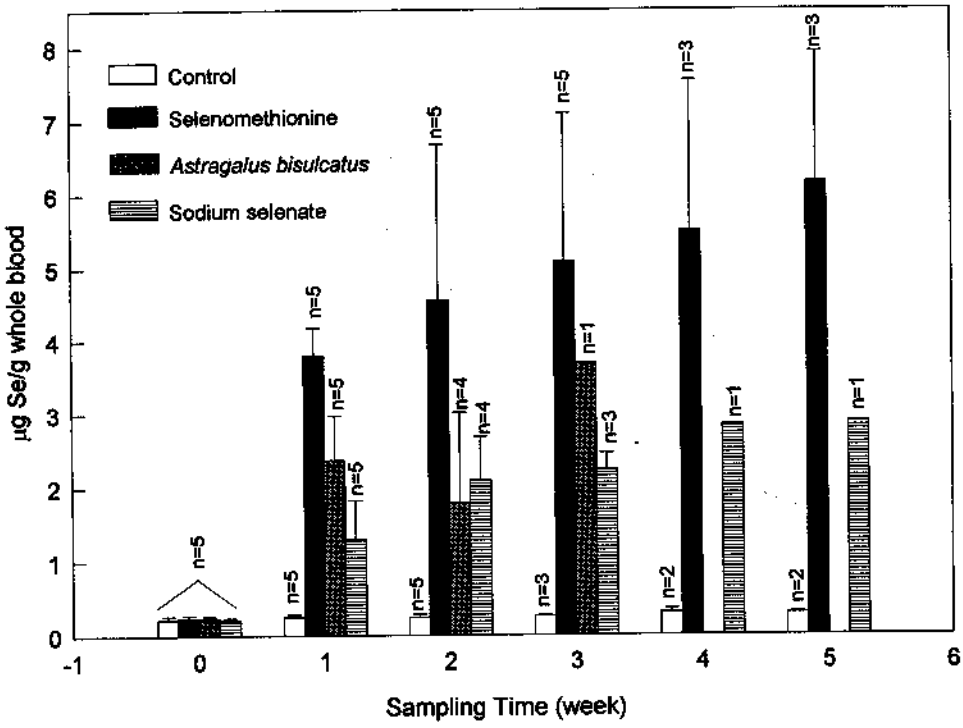

FIG. 4. Blood selenium concentrations at weekly intervals in pigs fed diets containing 25 µg Se/g in the forms of seleno-DL-methionine, *Astragalus bisulcatus*, and sodium selenate. At sampling times 3, 4, and 5 only one animal is represented for *A. bisulcatus* and sodium selenate, respectively.

(McConnell and Cho, 1965). The Sigma source of seleno-DL-methionine is approximately one-half D and one-half L form. Thus, the L form may be transported twice as rapidly as the D form.

The predominant form of Se in accumulator plant species such as *A. bisulcatus* is nonprotein, whereas the predominant form in nonaccumulator plant species such as wheat is protein bound. Olson *et al.* (1970) confirmed that much of the Se in naturally seleniferous wheat (up to 31 ppm) occurred in the gluten fraction and almost half was in the form of selenomethionine. Unfortunately, very little information is available concerning the chemical forms of the Se in plant tissues of nonaccumulator species. Likewise, there is apparently very little information about the chemical form of Se in animal tissues, an area of research needing further work.

The results presented in this report demonstrate individual animal susceptibility to Se and also suggest that the Se in *A. bisulcatus* has an absorption and tissue retention more closely related to sodium selenate than selenomethionine. This is supported by the pathological results and tissue Se values. Although the tissue and blood Se concentrations in the seleno-DL-methionine group were markedly higher than in either the *A. bisulcatus* or sodium selenate groups, severity of clinical signs and pathological lesions do not correlate with tissue Se levels. Even though uptake, storage, and retention are higher, the toxicity of the seleno-DL-methionine form of Se appears to be lower. The lesions of focal symmetrical poliomyelomalacia were most severe and more disseminated in the *A. bisulcatus* group, which also had polioencephalomalacia. Apparently, tissue levels of Se are not as important in the severity of clinical signs and lesions of induced poliomyelomalacia as is the form of Se ingested. Perhaps swainsonine (the toxin in locoweed) contributes to the severity and extent of the lesions in the *A. bisulcatus* group, but overt locoism was not observed.

ACKNOWLEDGMENTS

The authors thank Terrie Wierenga and Arlene Florence for technical assistance; Lew Dell Balls, Al Maciulis, and Tom Buck for animal care and handling; and Dr. Donald Sisson for statistical advice.

REFERENCES

Baker, D. C., James, L. F., Hartley, W. J., and Panter, K. E. (1989). Toxicosis in pigs fed selenium-accumulating plant species of sodium selenate. *Am. J. Vet. Res.* **50**, 1396–1399.

Combs, G. F., and Combs, S. B. (1986). *The Role of Selenium in Nutrition.* Academic Press, San Diego.

Hartley, W. J., James, L. F., Broquist, H., and Panter, K. E. (1984). Pathology of experimental locoweed and selenium poisoning in pigs. In *Plant Toxicology* (A. A. Seawright, M. P. Hegarty, L. F. James, and R. F. Keeler, Eds.), pp. 141–149. Queensland Poisonous Plant Committee, Yeerongpilly.

Herigstad, R. R., Whitehair, C. K., and Olson, O. E. (1973). Inorganic and organic selenium toxicosis in young swine: Comparison of pathologic

changes with those in swine with vitamin E deficiency. *Am. J. Vet. Res.* **34,** 1227–1238.

James, L. F., Hartley, W. J., and Van Kampen, K. R. (1981). Syndromes of *Astragalus* poisoning in livestock. *J. Am. Vet. Med. Assoc.* **178,** 146–150.

McConnell, K. P., and Cho, G. J. (1965). Transmucosal movement of selenium. *Am. J. Physiol.* **208,** 1191–1195.

Molyneux, R. J., James, L. F., and Panter, K. E. (1984). Chemistry of toxic constituents of locoweed (*Astragalus* and *Oxytropis*) species. In *Plant Toxicology* (A. A. Seawright, M. P. Hegarty, L. F. James, and R. F. Keeler, Eds.), pp. 266–278. Queensland Poisonous Plant Committee, Yeerongpilly.

Olson, O. E. (1969). Fluorometric analysis of selenium in plants. *J. Assoc. Off. Anal. Chem.* **52,** 627–634.

Olson, O. E., Novacek, E. J., Whitehead, E. I., and Palmer, I. S. (1970). Investigations on selenium in wheat. *Phytochemistry* **9,** 1181–1188.

Reasbeck, P. G., Barbezat, G. O., Robinson, M. F., and Thomson, C. D. (1981). Direct measurement of selenium absorption *in vivo:* Triple-lumen gut perfusion in the conscious dog. In *Proceedings New Zealand Workshop on Trace Elements,* p. 107. University Otago, Dunedin, NZ.

SAS (1987). *Stat Guide for Personal Computers,* Version 6 Edition. SAS Institute, Cary, NC.